Rotational Atherectomy remains the workhorse for severe coronary calcification

Chiung-Jen Wu, M.D. & Mohamed Abo bakr M.D.

Chang-Gung Memorial Hospital, Kaohsiung
Taiwan

TCTAP-2019 Hot topic: Calcification treatment
Apr. 28, 2019, Seoul, South Korea

Patient Profile

- Age: A 63 years old
- Gender: male
- Risk factor: DM, HTN, ESRD on P/D,
- LV EF: 45% , anterolateral wall hypokinesia

- Condition:
  - Recent NSTEMI cardiogenic shock, 3VD was Dx at other hospital, turn-down by CVS for CABG, and transferred to our center for considering of PCI

  - Shifted to transient H/D
  - IABP support
  - Dopamine I.V. support

TERUMO 6-7 Glidesheath via L't Snuffbox d-LRA

RCA

6Fr IL4 guiding catheter for both side coronary arteries

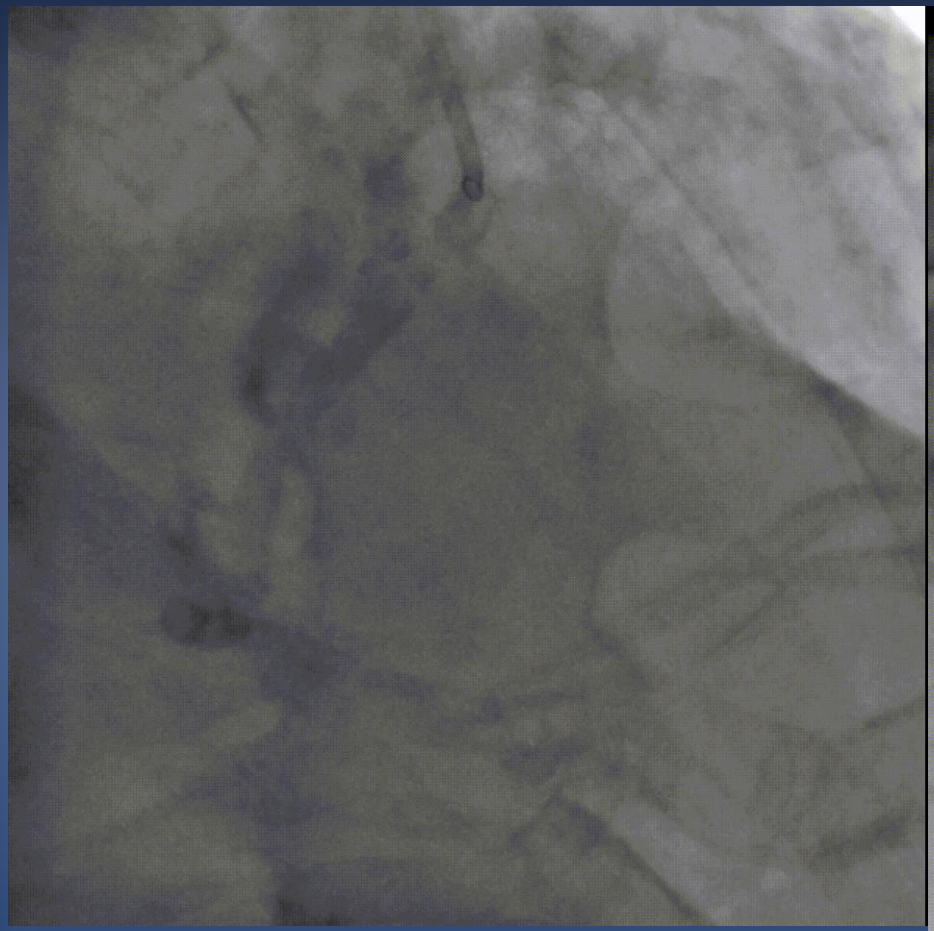

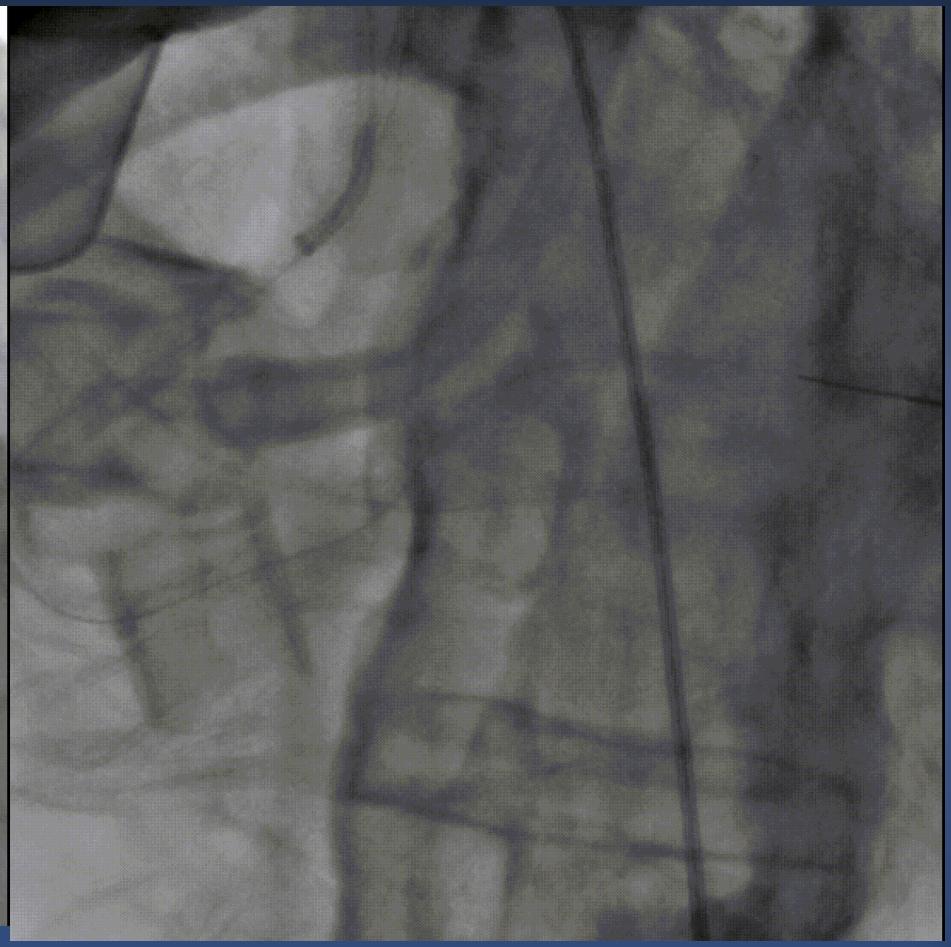

LCA

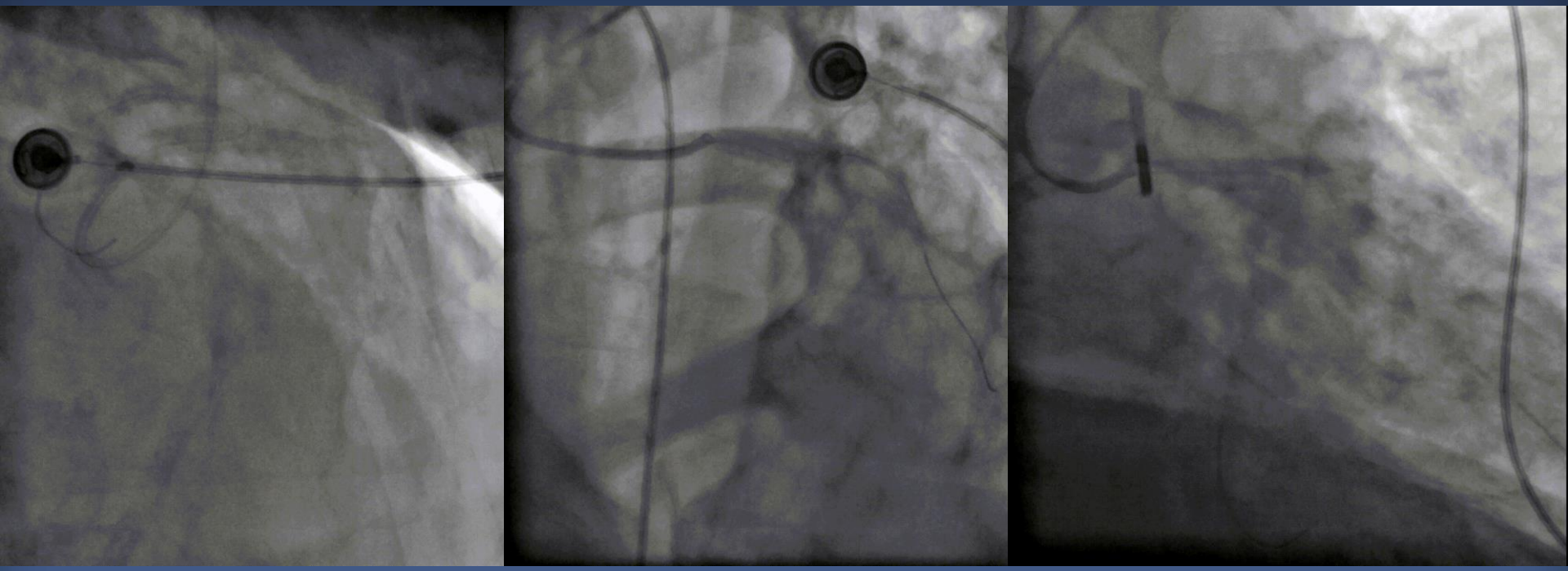

PCI to RCA first

PBOA with 2.0x20 mm and 3.0x20 mm HPB

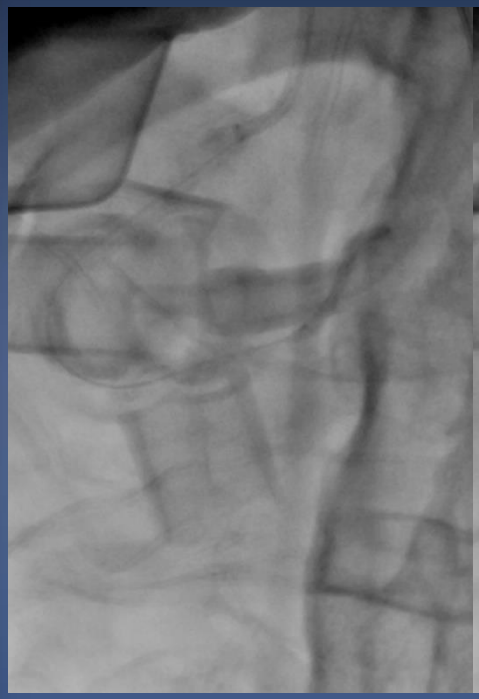
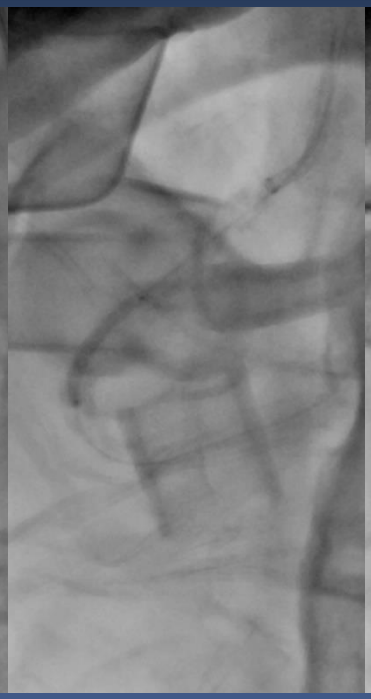

IVUS guided RCA stenting

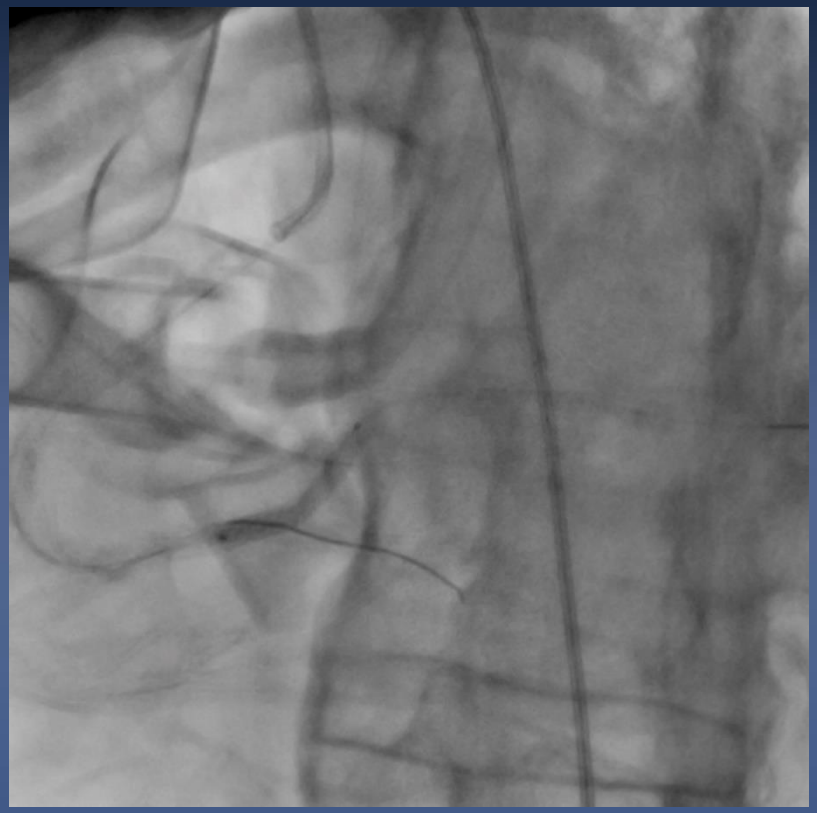

3.0x23 mm BMS , followed with 3.0x20 mm HPB

3.0x28 mm BMS , followed with 3.5x15 mm HPB

RCA Final angiogram

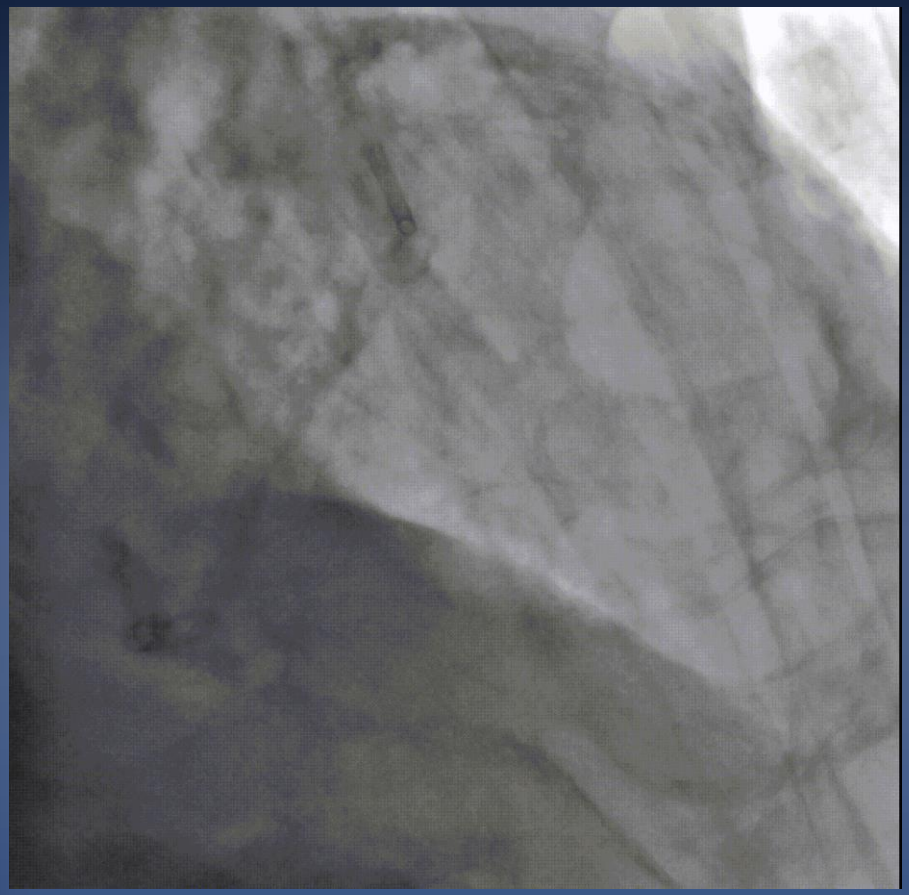

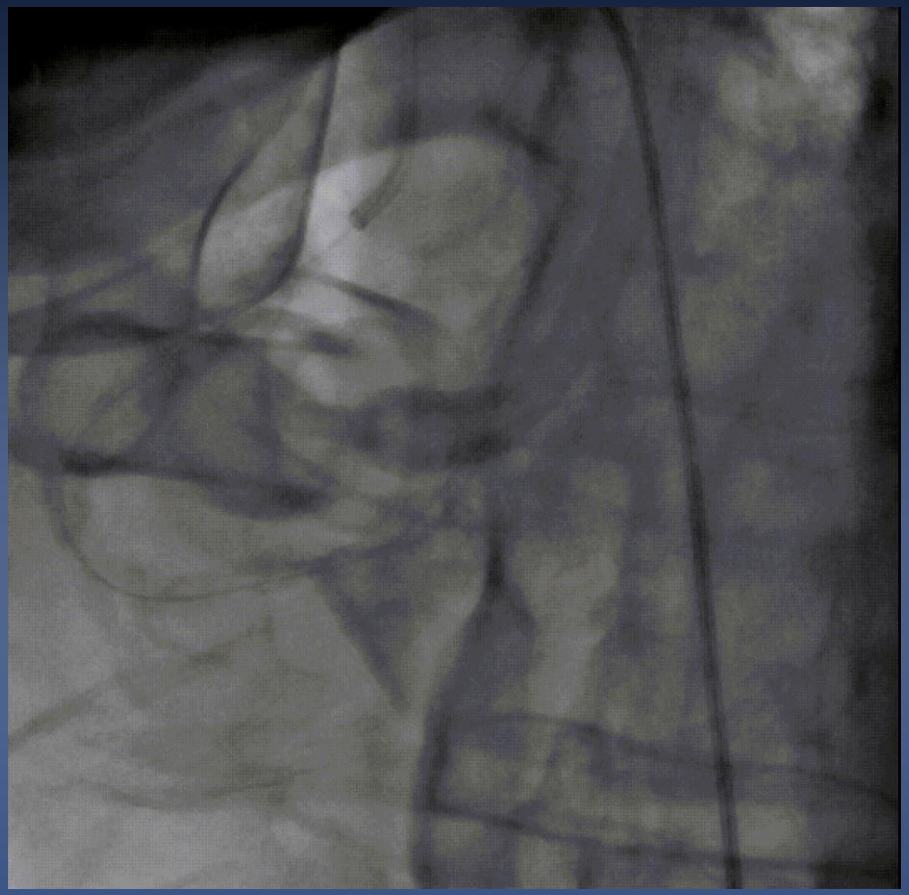

PCI to LCA (transient hypotension on LAD PCI)

Proximal LAD critical lesion with 2.5x15 mm NC-balloon un-dilatable

Mini-Trek 2.0x20 mm

Accuforce 2.5x15mm HPB

What is our next step

- POBA LCX first
- On VA-ECMO support via RFA/RFV
- Perform Rotablator atherectomy for un-dilatable LAD-p lesion

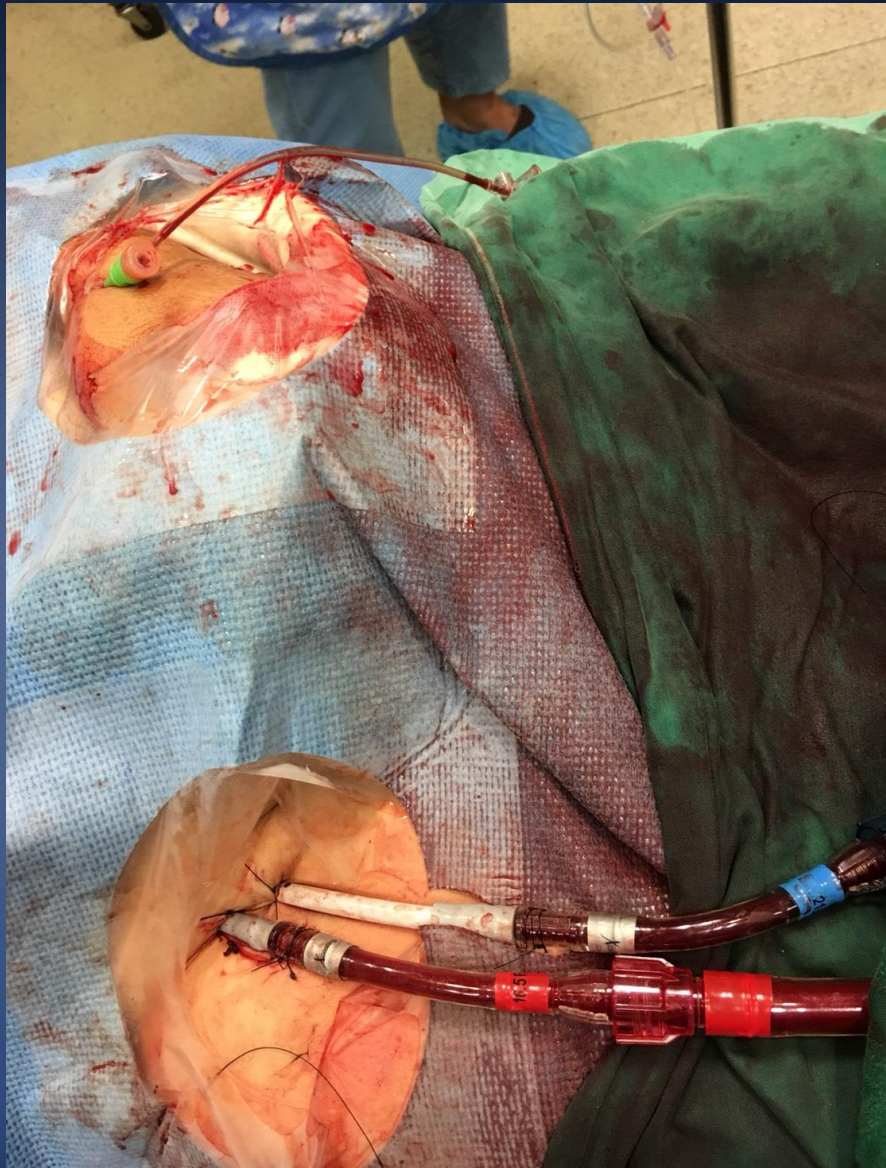

POBA LCX

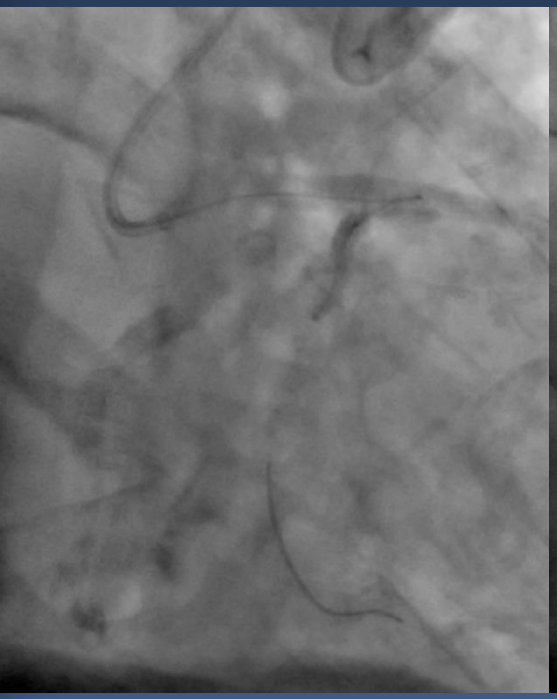

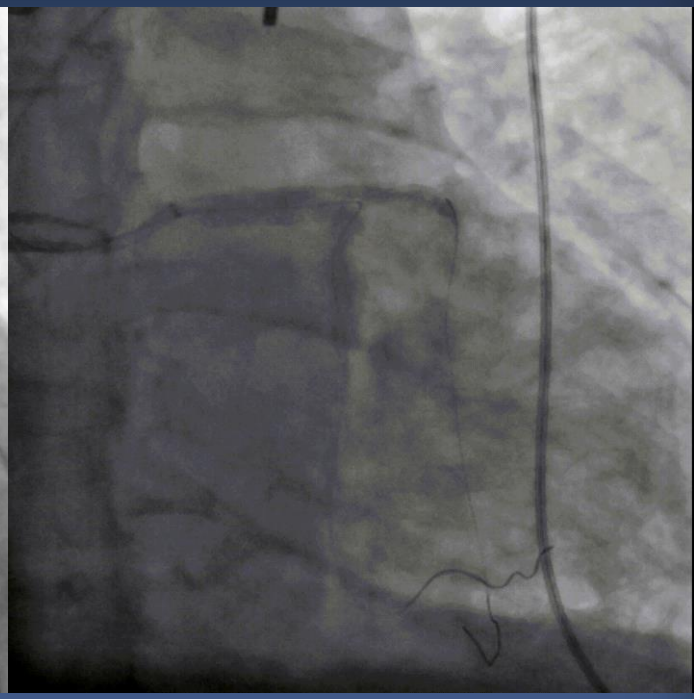

Rotablator burr was entrapped, s/p cut rotar shaft & 5F ST-01 deep intubation failed to remove 1.5 mm burr, VT Attack need DC shock with 200 J, BP = 80/50 mmHg

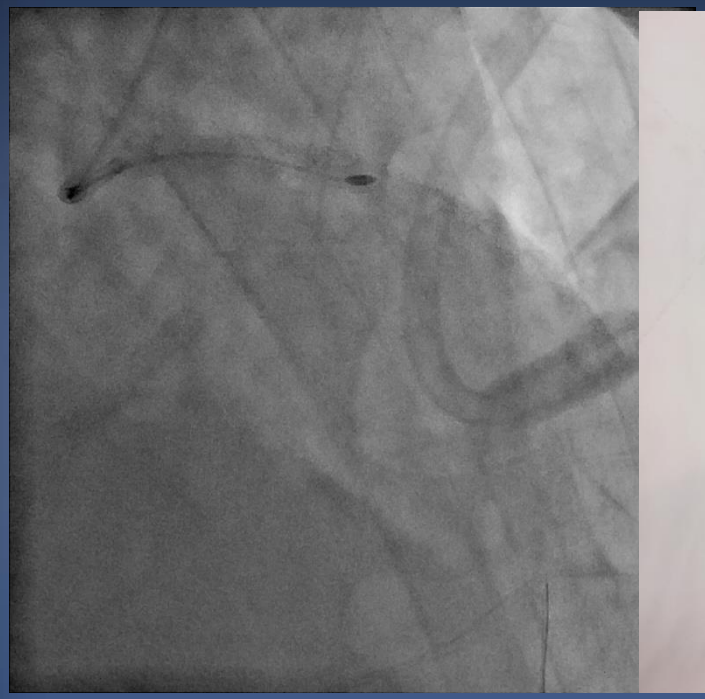

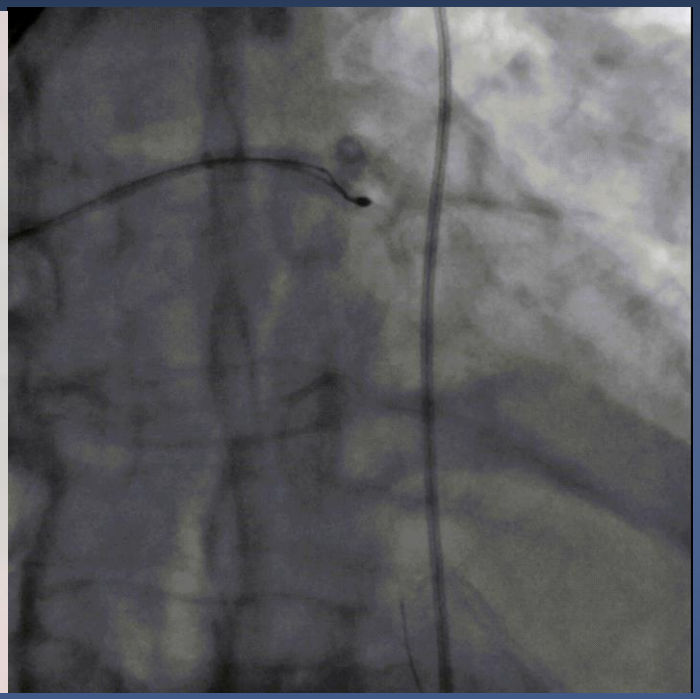

Rotablator burr 1.5 mm was entrapped at 3rd pass (Burr speed 180,000 rpm) due to angulated calcified lesion

UB3, Conquest pro & 8/20 guidewire intentionally punctured peri-burr hard tissue

CARDIOVASCULAR SUMMIT
TCT Asia
CVRF

About 20 mins later, rotablator burr was successfully removed by 5F ST-01 catheter, then, we try 1.5 mm rotar again…. For lesion modification

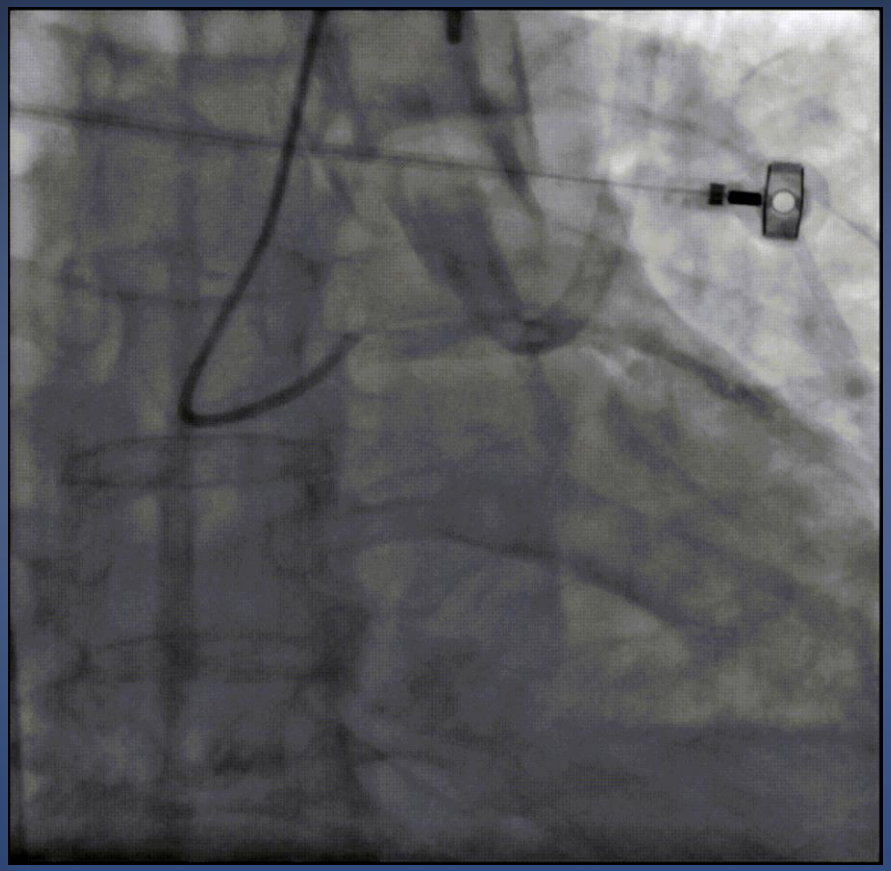

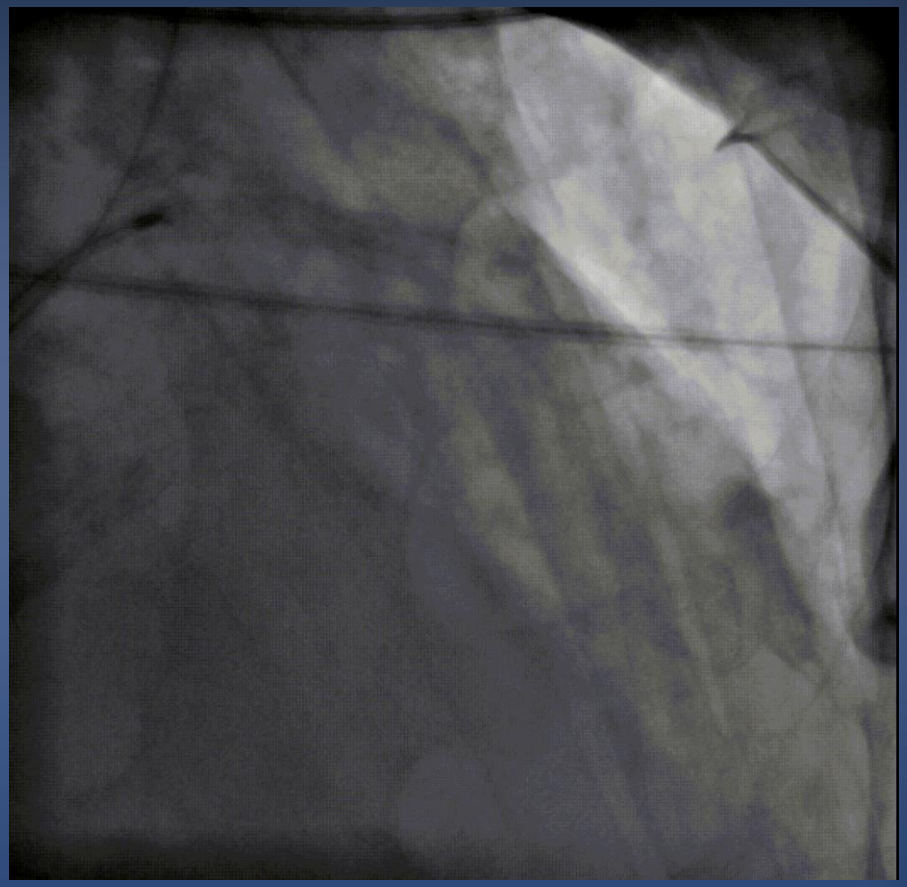

POBA again with NC-balloon 2.5x15 & 3 x15 mm became dilatable at 20 –24 atm

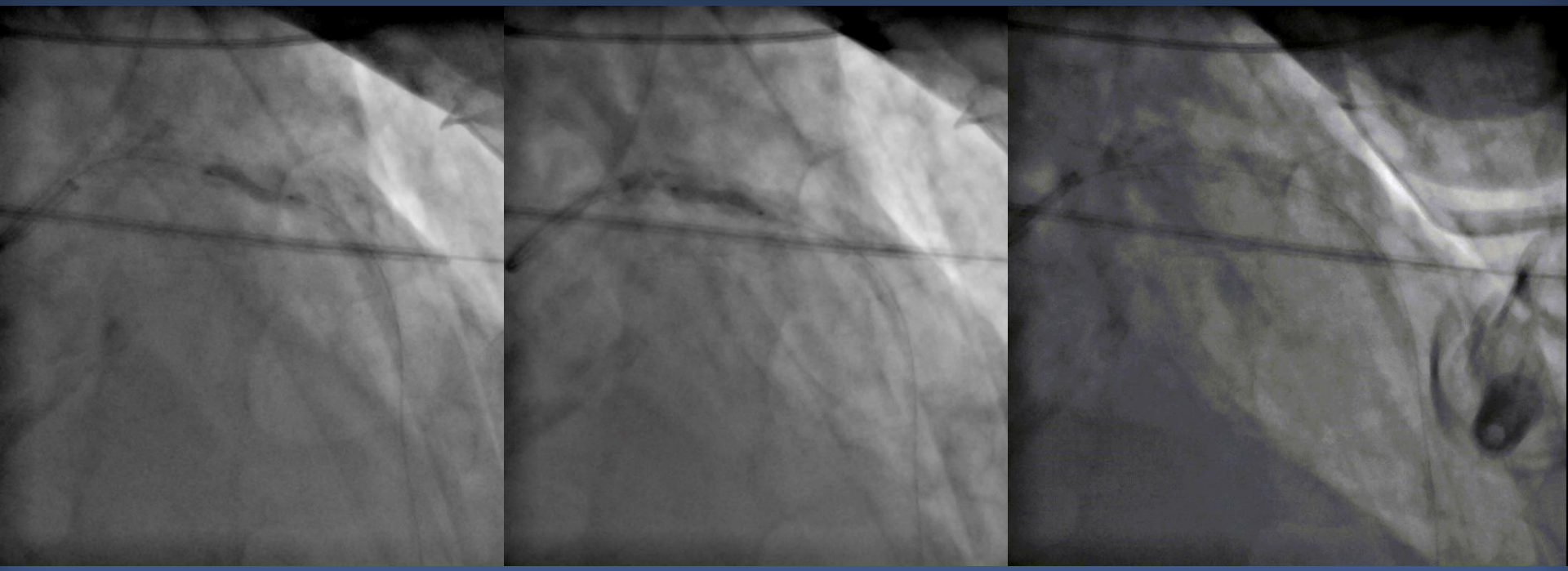

IVUS after Rotar & 3x15 mm HPB

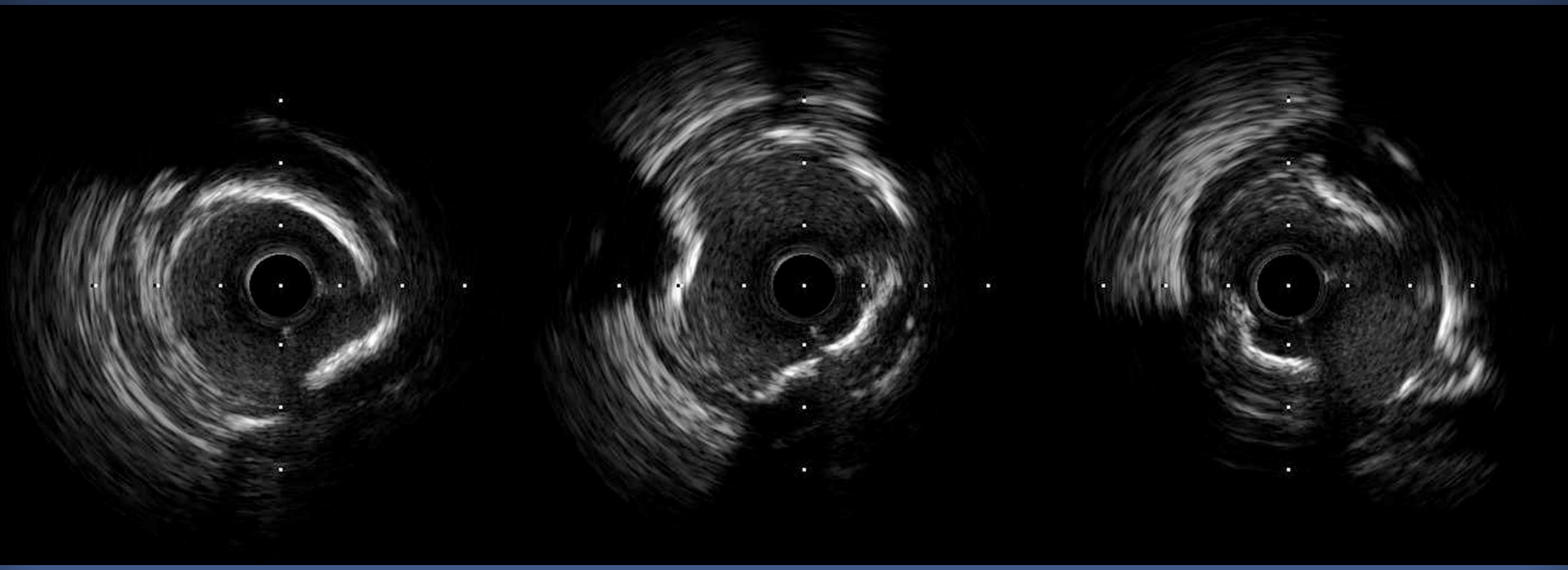

LAD stenting

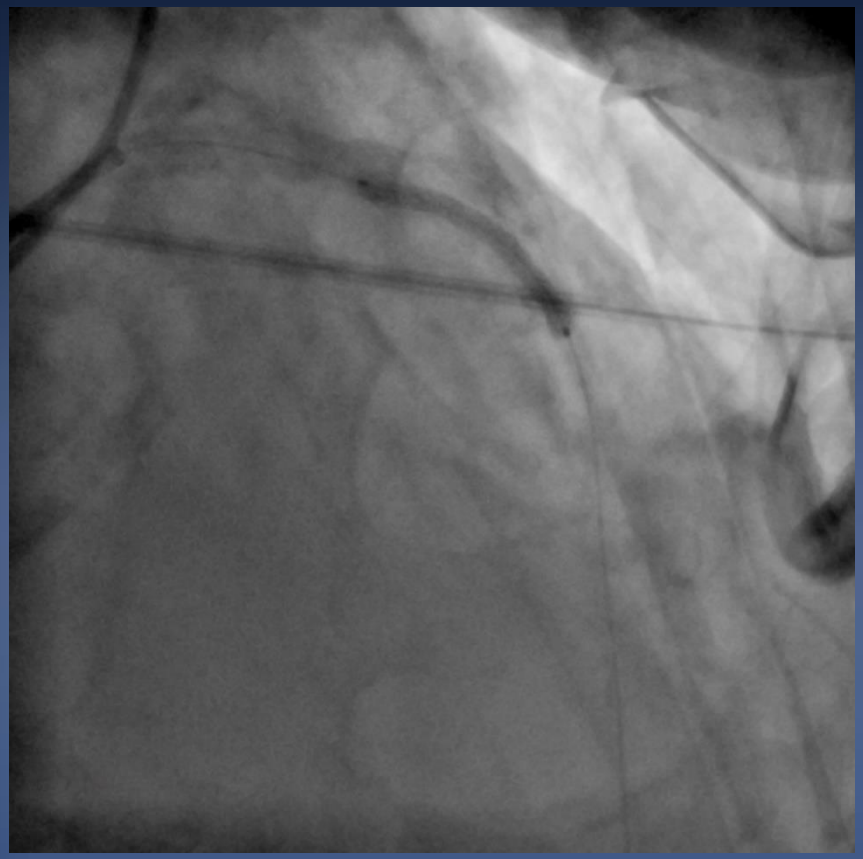

3.0x28 mm DES, followed with 3.0x15 mm HPB 20-24 atm

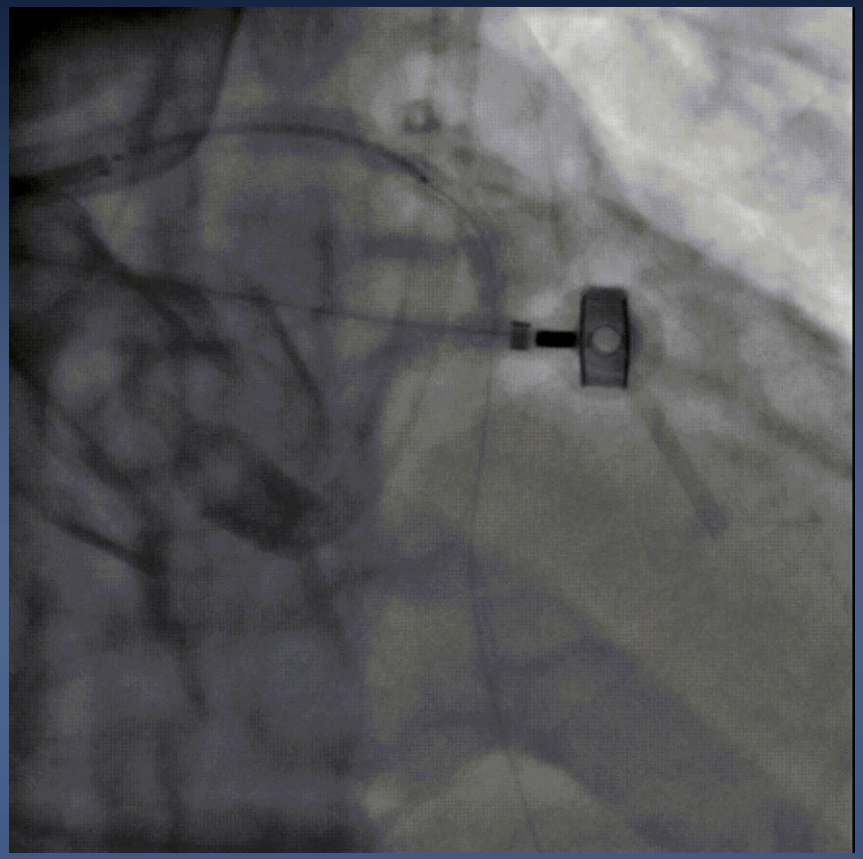

3.5x38 mm DES LM-LAD, followed with 3.5x15 mm HPB 20-28 atm

Post dilatation

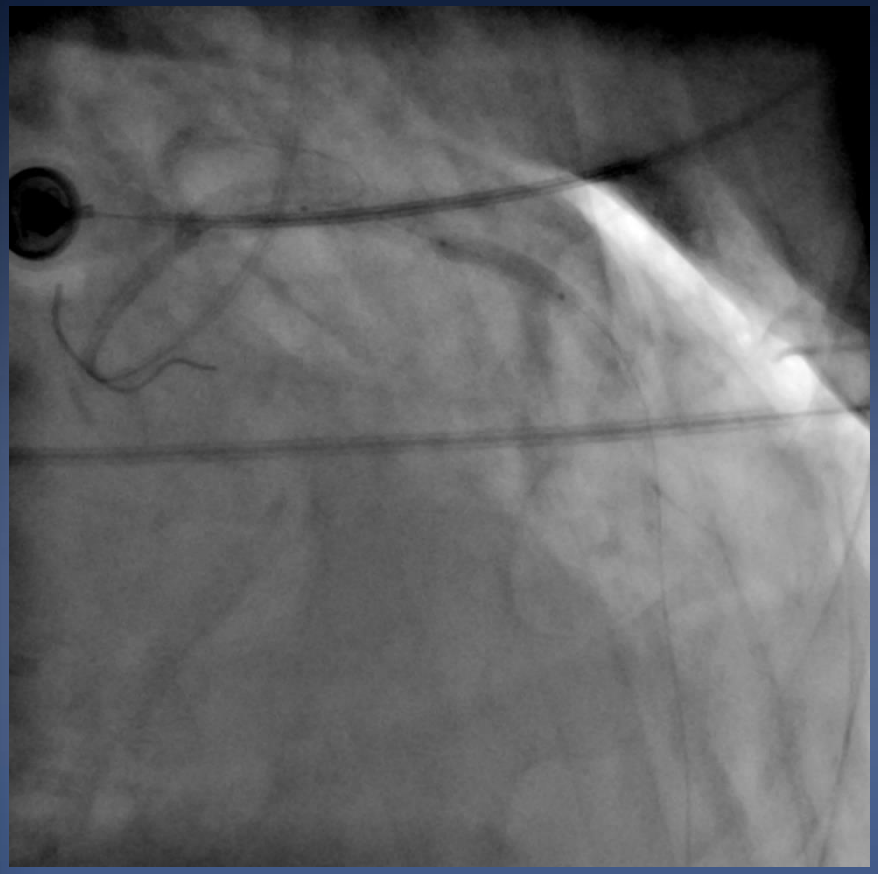

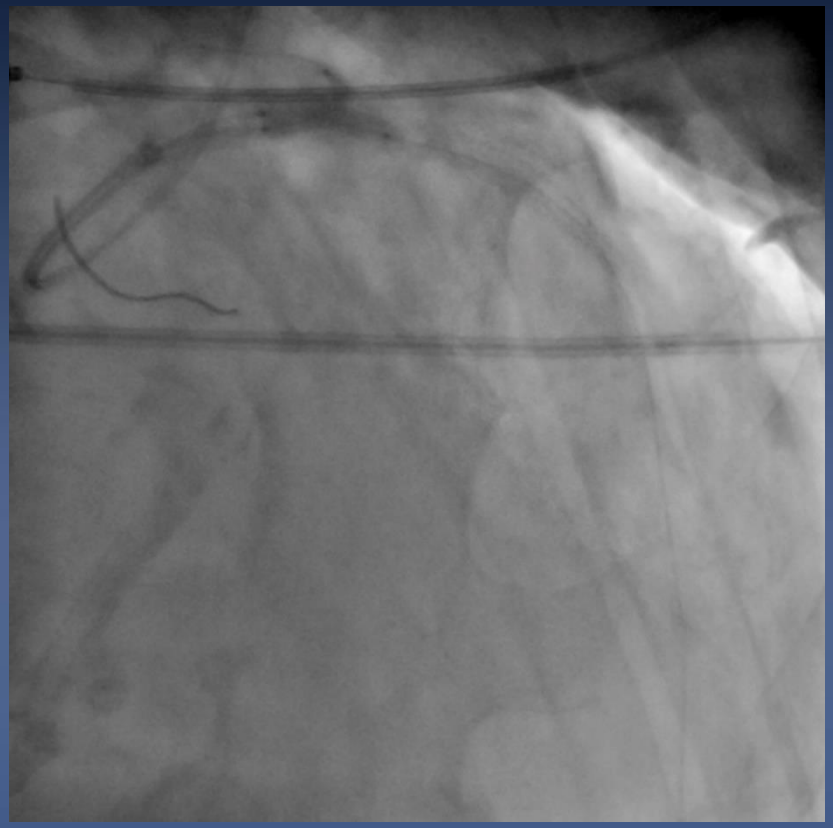

LM bifurcation Kissing balloon with 3.5x15 mm HPB & 2.5x15 mm regular balloon

Final angiogram

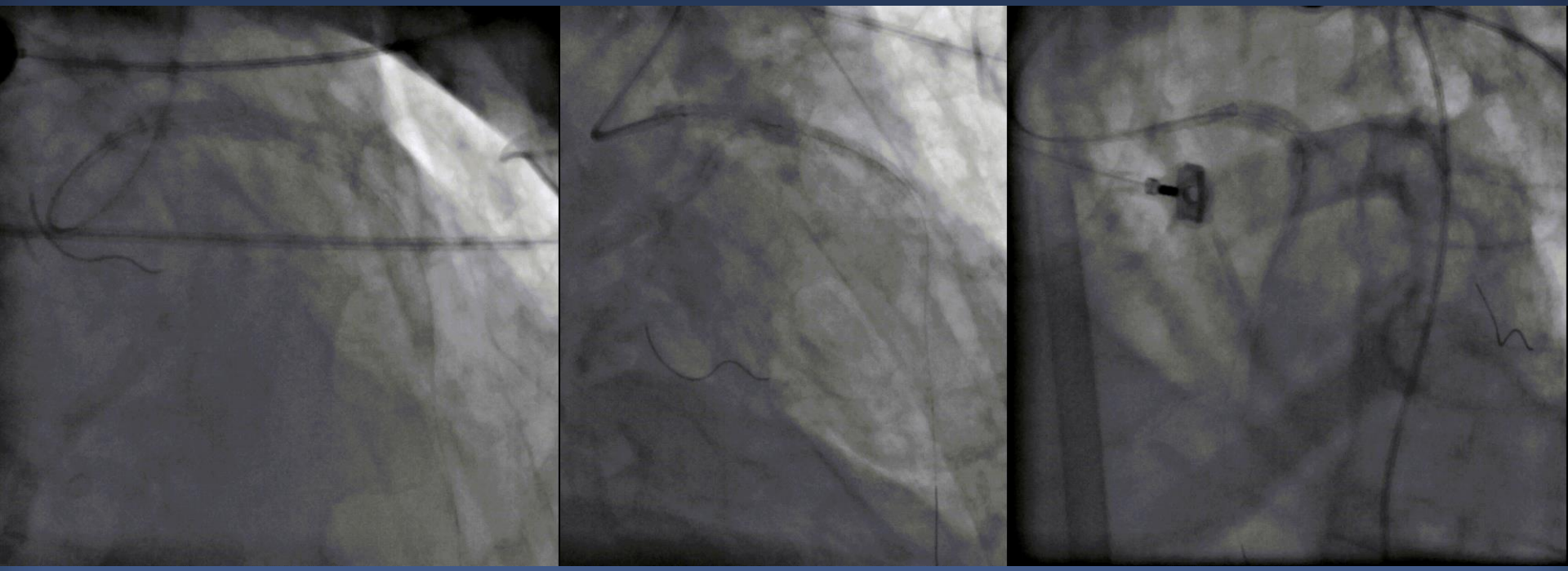

Summary PCI of the case:

- CHIP pt with underlying ESRD on P/D, non-STEMI refractory angina supported by LFA IABP, turn-down of urgent CABG by CVS and consider of PCI option
- Consult CVS again, but refused CABG option by pt and his family although high Syntax score & Euro score
- Fixed RCA by POBA and IVUS guided bail-out stenting first
- Tried POBA for CX & LAD, but un-dilatable at LAD-p due to calcification
- Set-up RFA/RFV VA-ECMO (unstable BP even with IABP) before rotar
- Rotar 1.5 mm burr incarceration due to angulation at LAD-p
- Failed to remove by deep intubated 5F ST-01 (Terumo Corp.) catheter, CP-12 & 8/20 intentionally puncture calcified lesion around trapped burr
- Removed 1.5 mm Rotar burr successfully, tried 2nd time 1.5 mm Rotar again

Conclusions:

- Hemodynamic support for CHIP pts during PCI is the must, active support by Impella should be better, but not available also higher price c/w VA-ECMO currently in Taiwan
- IABP support is available in most of the Centers in developing Countries, however less support as c/w ECMO & Impella
- Advancing Rotar burr need slow contact of the calcified lesion & avoid deceleration of burr run speed > 5,000 rpm
- Know how to dealing with Rotar Burr incarceration is very important
- Of course, emergent CABG is the last option, but higher risk of CABG must be considered

Take-Home Message

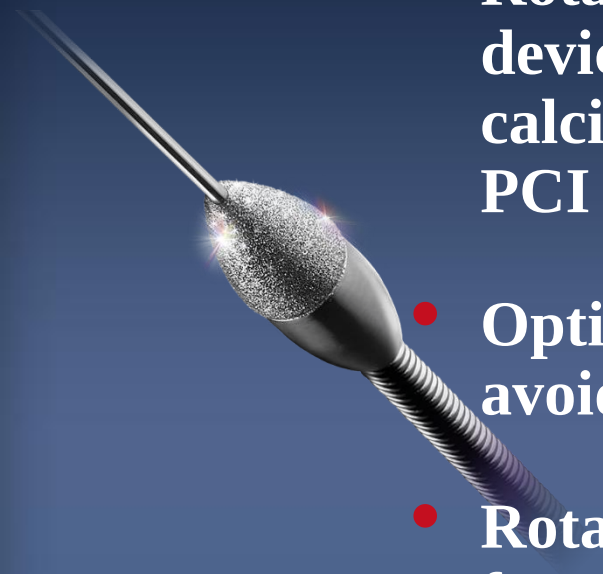

- Rotational atherectomy is a useful indispensable device in interventional treatment of heavily calcified lesions and essential tool for complex PCI
- Optimal technique and strategy are pivotal to avoid any potential complications
- Rotablation remains an important rescuer device for uncrossable or undilatable coronary lesions.
- Rotational atherectomy and complex PCI can be done smoothly using a single 6Fr Ikari-L guiding catheter

Thanks for your attention !
Welcome to Kaohsiung, Taiwan
ARIMURA